

## CASE REPORT

## Multiple Cutaneous Metastases from a Parotid Adenoid Cystic Carcinoma

Danyel Elias da Cruz PEREZ,<sup>1</sup> José MAGRIN,<sup>2</sup> Oslei Paes de ALMEIDA,<sup>3</sup> Luiz Paulo KOWALSKI<sup>2</sup>

Departments of <sup>1</sup>Stomatology, and <sup>2</sup>Head and Neck Surgery and Otorhinolaryngology, A. C. Camargo Cancer Hospital, <sup>3</sup>Oral Pathology, School of Dentistry of Piracicaba, University of Campinas, Piracicaba, Sao Paulo, Brazil

**Cutaneous metastasis from salivary gland adenoid cystic carcinoma is extremely rare. We report a case of a 39-year-old man that presented multiple cutaneous metastases from a parotid salivary gland adenoid cystic carcinoma. The clinical, histopathological and**

**immunohistochemical features are described and discussed. This case shows the importance of a detailed and periodical skin examination in patients treated for salivary gland adenoid cystic carcinoma. (Pathology Oncology Research Vol 13, No 2, 167–169)**

*Key words:* adenoid cystic carcinoma; cutaneous metastasis; cancer; cytokeratin; histopathology; immunohistochemistry

### Introduction

It is well known that adenoid cystic carcinoma (ACC) is a salivary gland tumor characterized by an indolent clinical course and poor long-term prognosis.<sup>9,12</sup> Distant metastases involve mainly the lungs, followed by bone, liver and brain. Cutaneous metastasis from salivary gland ACC is rare.<sup>3</sup> We describe a case of multiple cutaneous metastases of ACC from the parotid gland. This report illustrates the importance of careful skin examination during the follow-up of patients treated for ACC.

### Case report

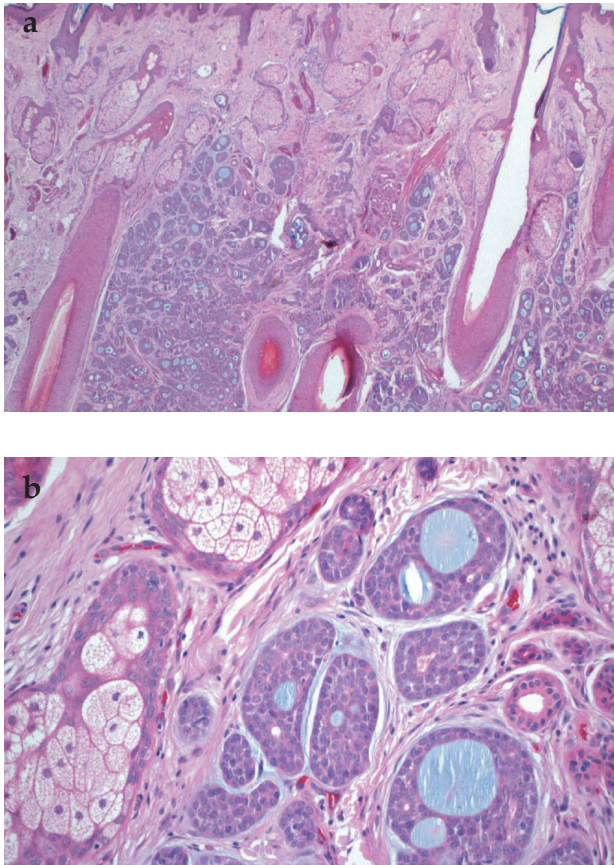
A 31-year-old man had been submitted to right parotidectomy and adjuvant radiotherapy in 1992 at another institution, because of an adenoid cystic carcinoma. The patient was referred to the Department of Head and Neck Surgery and Otorhinolaryngology, A. C. Camargo Cancer Hospital, Sao Paulo, Brazil, in February 2000, complaining of recent body weight loss (approximately 10 kg in 3 months) and chest pain. The loco-regional examination did not reveal

nodules or swelling in the patient's face. Chest radiography showed two, probably metastatic nodules sited in the left inferior lung lobe. Computed tomography confirmed the presence of the two nodules, measuring 1.0 cm and 2.0 cm in diameter. The patient was subjected to left inferior lung lobectomy, and the histopathological analysis confirmed lung metastasis of ACC. After 18 months (August 2001), the patient presented other distant metastasis in the lung, localized in the right upper lobe. A second thoracotomy was done for resection.

In June 2002, the patient complained of a nodular lesion located in the left shoulder. Clinical examination showed a subcutaneous, mobile, painless, well-demarcated nodule, 2.0 cm in extent. Lipoma, dermoid cyst and dermal metastasis of ACC were the main clinical differential diagnoses. Under local anesthesia, the nodule was fully removed. Microscopically, a fragment of skin covered by keratinized squamous epithelium was observed, presenting a neoplasm in the adjacent connective tissue, which infiltrated the reticular dermis, sebaceous glands and hair follicles (*Figs. 1a,b*). The neoplasm was composed of uniform basaloid cells arranged in a cribriform pattern. Cytologically, a small amount of cytoplasm, round and hyperchromatic nuclei were characteristic. This morphological appearance was consistent with the diagnosis of cutaneous metastasis of ACC. Perineural invasion was also observed. Immunohistochemical reactions for pan-cytokeratin (AE1/AE3), cytokeratin 7, vimentin and c-kit (CD117) were performed. The luminal cells were positive for cytokeratin 7 while non-

*Received:* Sept 7, 2006; *accepted:* March 10, 2007

*Correspondence:* Danyel Elias da Cruz PEREZ, Department of Stomatology – Hospital do Câncer A. C. Camargo, Rua Professor Antônio Prudente, 211. Liberdade, CEP: 01509-900, São Paulo/SP, Brazil. Tel: +55-11-2189-5129, fax: +55-11-3277-6789, E-mail: perezdec2003@yahoo.com.br



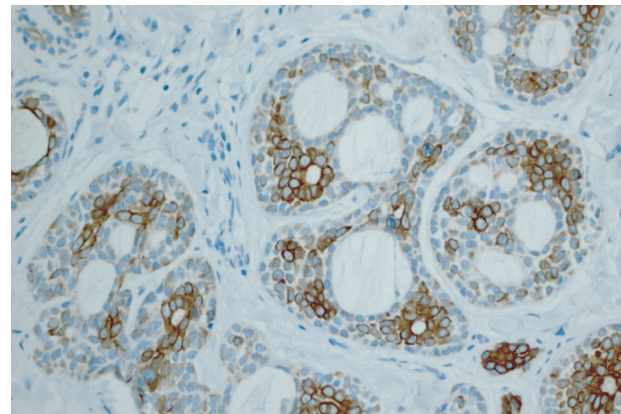
**Figure 1.** (a) Metastatic ACC infiltrating reticular dermis, sebaceous glands and hair follicles (hematoxylin-eosin, original magnification: x25). (b) High-power field showing metastatic ACC compressing adjacent sebaceous gland (hematoxylin-eosin, original magnification: x200)

luminal cells stained positive for vimentin (Figs. 2, 3). Both luminal and non-luminal cells showed strong immunoreactivity for pan-cytokeratin as well as a weak focal positivity for CD117 (Fig. 4). Positive and negative controls were applied in each reaction. Lung metastases also presented the same histopathological and immunohistochemical features. After 16 months, in October 2003, the patient noted subcutaneous nodules sited in the right elbow (0.7 cm) and mental region (0.5 cm). Both were surgically removed under local anesthesia, with the clinical hypothesis of metastasis of ACC. Histological analysis confirmed the clinical diagnosis. The patient is alive at present, without clinical and radiographic evidences of tumor recurrence twenty months after the last distant metastasis resection.

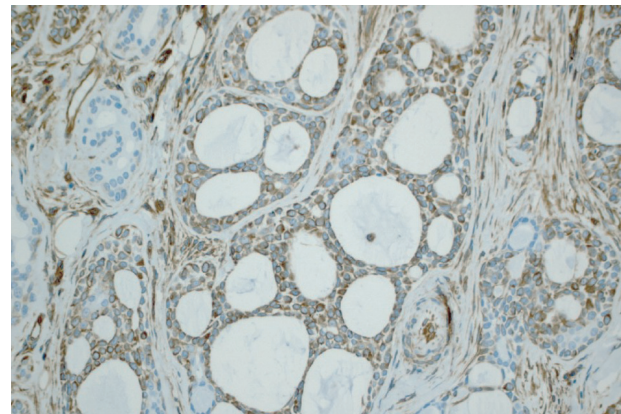
### Discussion

ACC is one of the commonest malignant salivary gland tumors, representing approximately 7.5% of the salivary gland malignancies.<sup>5</sup> ACC presents a slow and infiltrative

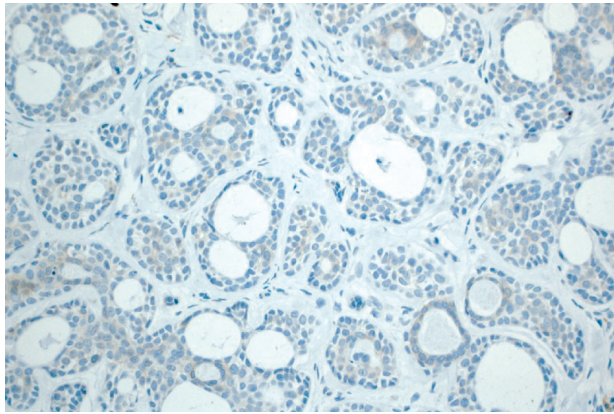
growth, with a relatively favorable survival rate at 5 years, but poor long-term outcome, due to frequent, late, local and distant recurrences.<sup>8</sup> The incidence of distant metastases varies between 24% and 52%. The lungs, bones, liver and brain are the commonest sites.<sup>8,15</sup> Subcutaneous ACC metastasis is extremely rare. Few cases of skin metastases of head and neck ACC have been described in the English-language literature.<sup>3,11,12</sup> It is difficult to affirm the real incidence of cutaneous ACC metastasis, because it is possible that in some large ACC series, not all sites of distant metastases are mentioned. Subcutaneous metastases from salivary gland malignancies represent about 2% of all cutaneous metastases in men and 1% in women.<sup>13</sup> Involvement of the subcutaneous tissue by ACC can occur due to direct extension of the tumor, distant metastasis or primary ACC of the skin. Both primary and metastatic skin ACC are very rare.<sup>4</sup> There are no histological differences between a primary tumor and cutaneous ACC metastasis, and a complete



**Figure 2.** Luminal cells of ACC showing strong positivity for cytokeratin 7 (streptavidin-biotin-peroxidase method, original magnification: x200)



**Figure 3.** Tumor cells presenting strong expression of vimentin (streptavidin-biotin-peroxidase method, original magnification: x200)



**Figure 4.** ACC cells positive for c-kit (CD117) (streptavidin-biotin-peroxidase method, original magnification: x200)

medical history of the patient is essential for the final diagnosis.<sup>3</sup> Generally, the histological diagnosis of salivary gland tumors is made by analyzing the morphological features of the tumor, and using special stains such as periodic acid-Schiff (PAS) and mucicarmine. In some cases, however, immunohistochemical markers can be useful, mainly when the tumor is at an unusual site. In ACC, due to involvement of myoepithelial cells in the development of the tumor, most of the cells are positive for AE1/AE3 and vimentin. In cribriform and tubular ACC, only luminal cells present positivity for cytokeratin 7, similarly to normal luminal ductal salivary gland cells, while vimentin is expressed in non-luminal cells, the commonest cells in ACC.<sup>2</sup> This immunoprofile was found in the present case as well.

Treatment of patients with distant metastases remains unresolved, since more often than not they present concomitant local and distant recurrences. ACC is unresponsive to anti-neoplastic drugs usually used in chemotherapeutic regimens.<sup>14,15</sup> A transmembrane receptor tyrosine kinase named KIT, has been found in ACC. KIT, which is the product of the proto-oncogene c-kit, can be immunohistochemically detected by the antibody against CD117. As occurred in the present case, a high percentage of c-kit-positive ACC suggest that this proto-oncogene could be associated with the development of this tumor.<sup>6</sup> Recently, a specific inhibitor of the bcr-abl autophosphorylation, platelet-derived growth factor receptor (PDGFR), and c-kit tyrosine kinases, named imatinib mesylate was developed.<sup>7,10</sup> In patients with unresectable or metastatic ACCs that overexpress CD117, good results were observed with the oral administration of imatinib mesylate.<sup>1</sup> Other authors did not, however, obtain the expected success with this drug,<sup>7,10</sup> perhaps because the c-kit-positive ACC lacked activating mutations of c-kit or PDGFR-alpha gene.<sup>10</sup> Further phase 2 studies using imatinib mesylate are needed in patients with c-kit-positive ACC to evaluate the

real efficacy of this drug. On the other hand, when there is isolated metastasis, surgical resection may be considered, as was performed in the present case.

Patients previously treated for malignant tumors, especially ACC, must have the skin carefully examined during the follow-up. Although extremely rare, multiple or single subcutaneous nodules can be ACC metastases. Circumscribed cutaneous ACC metastases are successfully treated by surgery with a good control of the disease.

### References

1. Alcedo JC, Fábrega JM, Arosemena JR, Urrutia A: Imatinib mesylate as treatment for adenoid cystic carcinoma of the salivary glands: report of two successfully treated cases. *Head Neck* 26:829-831, 2004
2. Araujo VC, Sousa SOM, Carvalho, Araujo NS: Application of immunohistochemistry to the diagnosis of salivary gland tumors. *Appl Immunohistochem Mol Morphol* 8:195-202, 2000
3. Chang CH, Liao YL, Hong HS: Cutaneous metastasis from adenoid cystic carcinoma of the parotid gland. *Dermatol Surg* 29:775-779, 2003
4. Doganay L, Bilgi S, Aygit C, Altaner S: Primary cutaneous adenoid cystic carcinoma with lung and lymph node metastases. *J Eur Acad Dermatol Venereol* 18:369-371, 2004
5. Ellis GL, Auclair P: Tumors of the salivary glands: Atlas of Tumor Pathology. Washington, DC: Armed Forces Institute of Pathology, 3<sup>rd</sup> Series, Fascicle 17, 1996
6. Holst VA, Marshall CE, Moskaluk CA and Frierson HF Jr: KIT protein expression and analysis of c-kit gene mutation in adenoid cystic carcinoma. *Mod Pathol* 12:956-960, 1999
7. Hote SJ, Winquist EW, Lamont E, MacKenzie M, Vokes E, Chen EX, Brown S, Pond GR, Murgo A, Siu LL: Imatinib mesylate in patients with adenoid cystic cancers of the salivary glands expressing c-kit: A Princess Margaret Hospital phase II consortium study. *J Clin Oncol* 23:585-90, 2005
8. Khan AJ, DiGiovanna MP, Ross DA, Sasaki CT, Carter D, Son YH, Haffty BG: Adenoid cystic carcinoma: a retrospective clinical review. *Int J Cancer* 96:149-158, 2001
9. Kokemueller H, Eckardt A, Brachvogel P, Hausamen JE: Adenoid cystic carcinoma of the head and neck – a 20 years experience. *Int J Oral Maxillofac Surg* 33:25-31, 2004
10. Lin CH, Yen RF, Jeng YM, Tzen CY, Hsu C, Hong RL: Unexpected rapid progression of metastatic adenoid cystic carcinoma during treatment with imatinib mesylate. *Head Neck* 27:1022-1027, 2005
11. Nakamura M, Miyachi Y: Cutaneous metastasis from an adenoid cystic carcinoma of the lacrimal gland. *Br J Dermatol* 141:350-351, 1999
12. Nascimento AG, Amaral ALP, Prado LAF, Kligerman J, Silveira TR: Adenoid cystic carcinoma of the salivary glands. A study of 61 cases with clinicopathologic correlation. *Cancer* 57:312-319, 1986
13. Schwartz RA: Cutaneous metastatic disease. *J Am Acad Dermatol* 33:161-182, 1995
14. Spiers AS, Esseltine DL, Ruckdeschel JC, Davies JN, Horton J: Metastatic adenoid cystic carcinoma of salivary glands. Case reports and review of the literature. *Cancer Control* 3:336-342, 1996
15. Spiro RH: Distant metastasis in adenoid cystic carcinoma of salivary origin. *Am J Surg* 174:495-498, 1997